

# Comparison of Efficacy of Buccal Fat Pad and Collagen Membrane in Surgical Management of Oral Submucous Fibrosis

<sup>1</sup>Rajbir K Randhawa, <sup>2</sup>Gagandeep S Randhawa, <sup>3</sup>Saba Tiwari, <sup>4</sup>KC Gupta, <sup>5</sup>Anisha Maria, <sup>6</sup>Mrinal Satpathy

## ABSTRACT

**Background and objectives:** Oral submucous fibrosis (OSMF) is a chronic progressive premalignant condition, characterized by gradual trismus of mouth. The study was done to compare the efficacy of buccal fat pad (BFP) and collagen membrane as an interpositional material in surgical management of OSMF and also (1) to assess and compare the mouth opening achieved in both groups of patient; (2) the improvement in flexibility of buccal mucosa in both groups; (3) oral pain and burning sensation on intake of spicy food; (4) the rapidity in epithelialization of graft at the intraoral wound site.

**Materials and methods:** Thirty patients were randomly divided into 15 patients each in groups I and II respectively. Group I patients received BFP as the interpositioning material, whereas group II received xenogenous collagen membrane after bilateral excision of bands. Group I was compared with group II postoperatively for mouth opening up to 6 months follow-up.

**Results:** Collagen membrane group showed better mouth opening postoperatively owing to their faster epithelialization rate and less wound contracture.

**Conclusion:** The collagen membrane (group II) proved to more efficient and the result was statistically significant as it showed better mouth opening postoperatively at 6 months, improvement in flexibility of buccal mucosa, reduction in postoperative pain and burning sensation, and faster epithelialization rate compared with BFP (group I).

**Keywords:** Buccal fat pad, Collagen membrane, Mouth opening, Oral submucous fibrosis.

**How to cite this article:** Randhawa RK, Randhawa GS, Tiwari S, Gupta KC, Maria A, Satpathy M. Comparison of Efficacy of Buccal Fat Pad and Collagen Membrane in Surgical Management of Oral Submucous Fibrosis. *Int J Prev Clin Dent Res* 2017;4(3):210-217.

**Source of support:** Nil

**Conflict of interest:** None

## INTRODUCTION

In 1952, Schwartz described five Indian women from Kenya with a condition of the oral mucosa including the palate and pillars of the fauces, which he called "atrophia idiopathica (tropica) mucosae oris." Later it was termed oral submucous fibrosis (OSMF).<sup>1</sup>

The OSMF is a disease with uncertain etiology, i.e., often encountered in practice in India. It is one of the precancerous conditions leading to carcinoma of cheek. It is caused by chewing irritants like tobacco, betel leaf with lime, and areca nut.<sup>2-5</sup> These substances trigger the synthesis of collagen, tough fibrinous protein that stiffens the soft mucous membrane and muscles of the oral cavity. The tongue being highly vascular usually escapes. The mouth size shrinks in extreme cases; only a button size opening is left. There is scarring with atrophy of the mucous membrane and pain during swallowing, preventing the patient from enjoying their meal. The atrophic mucous may ulcerate often, and subsequently may lead to malignancy.<sup>6,7</sup>

The frequency of malignant change in patients with OSMF ranges from 3 to 6%. Sixty-six patients with OSMF were followed up for a period of 17 years by Murti et al, who recorded a malignant transformation rate of 7.6%. With a longer follow-up of the same group, the malignant transformation rates could increase further.<sup>1</sup>

Various medical and surgical modalities have been advocated, but the present study is conducted with the aim of achieving results in terms of mouth opening after transecting the fibrous bands followed by grafting using buccal fat pad (BFP)/collagen and comparing their roles in achieving the same.<sup>8,9</sup>

<sup>1,2</sup>Senior Lecturer, <sup>3,6</sup>Assistant Professor, <sup>4</sup>Professor, <sup>5</sup>Principal and Head

<sup>1,2</sup>Department of Oral and Maxillofacial and Reconstructive Surgery, Ahmedabad Dental College & Hospital, Ahmedabad Gujarat, India

<sup>3</sup>Department of Oral and Maxillofacial and Reconstructive Surgery, L.N. Medical College and Research Centre, Bhopal Madhya Pradesh, India

<sup>4</sup>Department of Oral and Maxillofacial and Reconstructive Surgery, Modern Dental College & Research Centre, Indore Madhya Pradesh, India

<sup>5</sup>Department of Oral and Maxillofacial and Reconstructive Surgery, Rishiraj College of Dental Sciences & Research Centre Bhopal, Madhya Pradesh, India

<sup>6</sup>Department of Oral and Maxillofacial and Reconstructive Surgery People's Dental Academy, Bhopal, Madhya Pradesh, India

**Corresponding Author:** Rajbir K Randhawa, Senior Lecturer Department of Oral and Maxillofacial and Reconstructive Surgery Ahmedabad Dental College & Hospital, Ahmedabad, Gujarat India, Phone: +919065999990, e-mail: dr.randhawa23@gmail.com

## MATERIALS AND METHODS

The study comprising 30 subjects was carried out in the Department of Oral and Maxillofacial Surgery. Approval for this study was obtained from the ethical committee of college. Thirty patients were randomly divided into 15 patients each in groups I and II respectively. Group I patients received BFP as the interpositioning material, whereas group II received xenogenous collagen membrane after bilateral excision of bands.

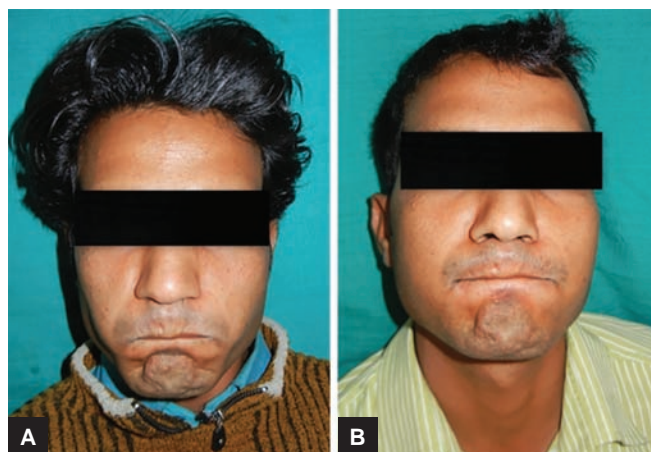### Inclusion Criteria

- Thirty subjects with clinically and histologically proven bilateral OSMF.
- Patients of age between 20 and 50 years, of either sex with mouth opening less than 25 mm were treated surgically under general anesthesia.
- Patients who had given up their abusive habits were selected.
- All patients were explained about the procedure and informed consent was obtained from each patient.
- Cases selected were in good health, none of the patients presented with evidence of systemic disease, deficiencies, or frank oral infection.
- The Khanna and Andrade<sup>10</sup> classification for OSMF was followed.

### Method of Study

Only Grade III and Grade IVa patients were included in the study. A detailed history was obtained from each patient with special reference to their habits and duration, and the patients were asked to discontinue the habit before the procedure. Routine hemogram, urine examination, and clinical examination were done to rule out any associated systemic diseases.

The local examination included distribution of fibrous bands, sites of involvement, and the interincisal distance (ID) between the incisal edges of the maxillary and mandibular central incisors, which were measured



**Figs 1A and B:** Preoperative and postoperative blowing of cheeks

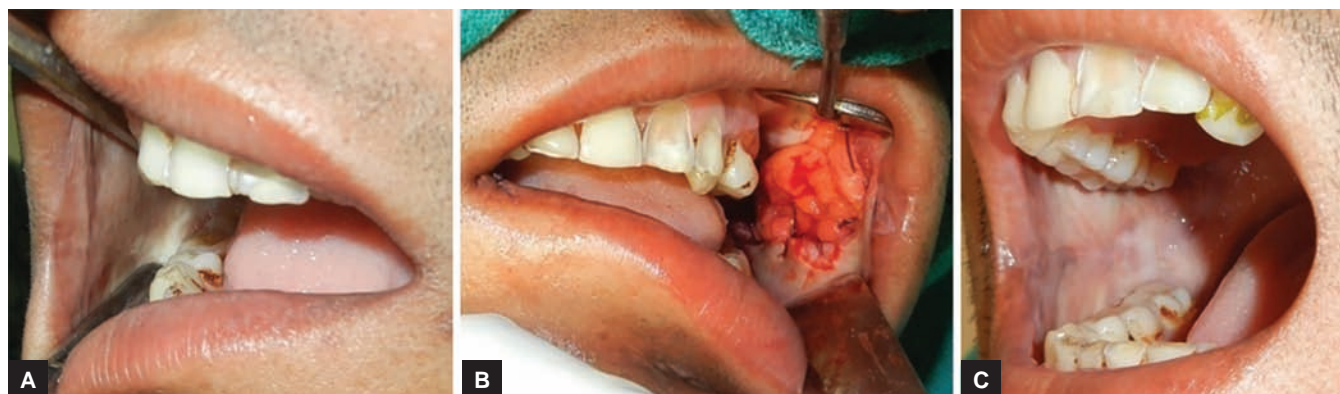
using a simple ruler and expressed in millimeters. Also the patients were asked to blow the cheeks to check for flexibility of buccal mucosa, and presence of pain and burning sensation was noted.

Patients were clinically followed up postoperatively at third day, 1, 3 months, and 6 months. At above-mentioned various intervals, mouth opening was measured visually with metal scale from incisal edges; subjective note of pain and burning sensation obtained; and flexibility of oral mucosa checked by asking the patients to blow the cheeks. Epithelialization was assessed visually daily till complete epithelialization had occurred (Figs 1 and 2).

### Materials used

Group I – Harvested autologous BFP

Group II – Xenogenous collagen membrane (5 × 5 cm) marketed by EUCARE Pharmaceuticals Private Limited. The collagen membranes come in varying dimension of 5 × 5, 10 × 10, and 25 × 25 cm, and its thickness is 0.6 mm. It is sterilized by ethylene oxide and gamma irradiation and is marketed in form-fill seal aluminum pouch packing containing a mixture of isopropyl alcohol and water; it



**Figs 2A to C:** Epithelialization of buccal fat pad within 4 weeks

has a shelf life of over 5 years. Before use, it is washed with sterile normal saline.<sup>11-14</sup>

## SURGICAL PROCEDURE

The surgery was performed under general anesthesia. The fibrous bands were palpated to assess the extent of the incision. The incisions were made bilaterally using no. 15 Bard Parker blade along each side of buccal mucosa at the level of occlusal plane away from the Stenson's orifice. The incision extended posteriorly to pterygo-mandibular raphe (or) anterior pillar of the fauces and anteriorly as far as the angle of the mouth, depending upon the location of the fibrotic bands which restricted the mouth opening. The incision was carried out to the depth of the submucosal layer, and the wound created was further freed by manipulation using fingers until no restriction was felt. After release of fibrous bands, extraction of all third molars was done.

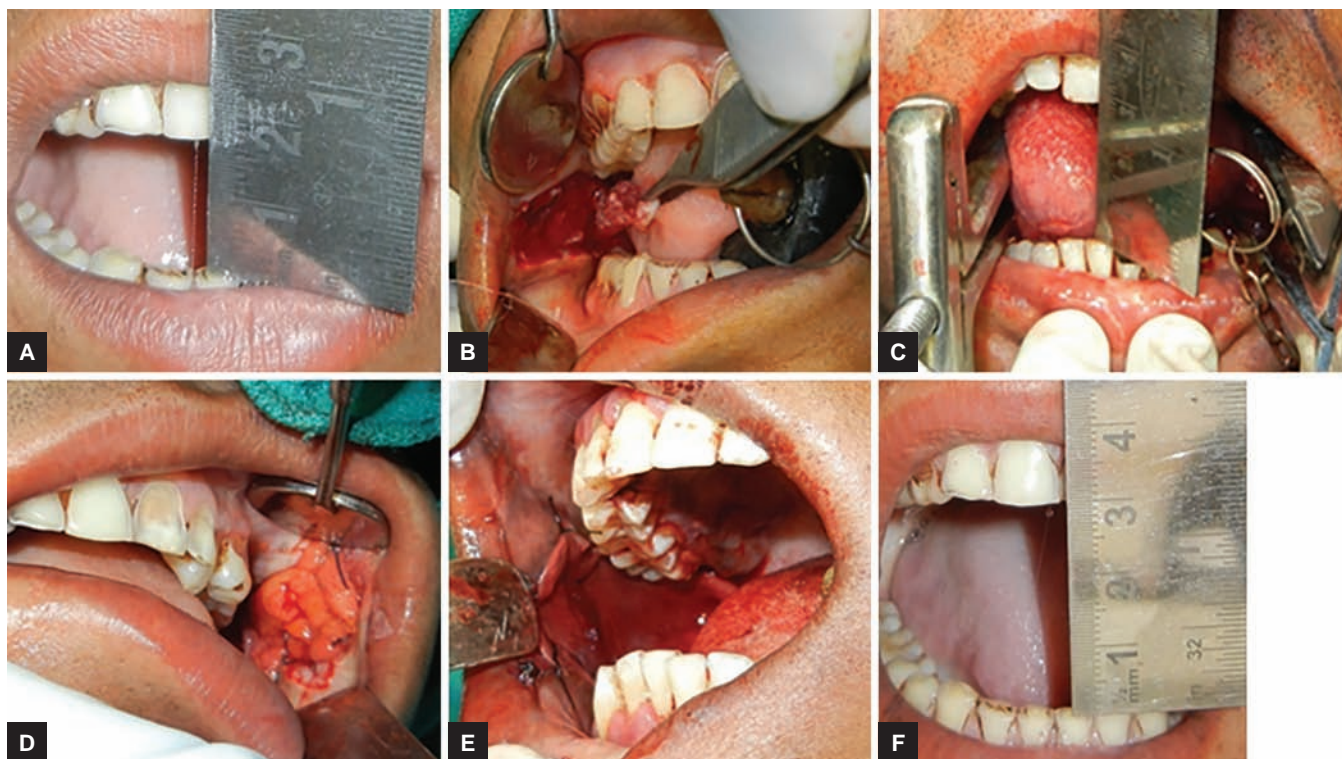
The mouth was then forced to open using Heister's mouth gag to an acceptable range of approximately 35 mm. The coronoid processes were approached from wound created and resected if a 35 mm mouth opening could not be achieved. A mouth opening of 35 mm as measured was considered to be the minimum acceptable opening in an adult.<sup>15-17</sup> Then the mouth opening was measured from incisal edges intraoperatively.

In group I patients, following excision of fibrotic bands and forcible mouth opening, the BFP was

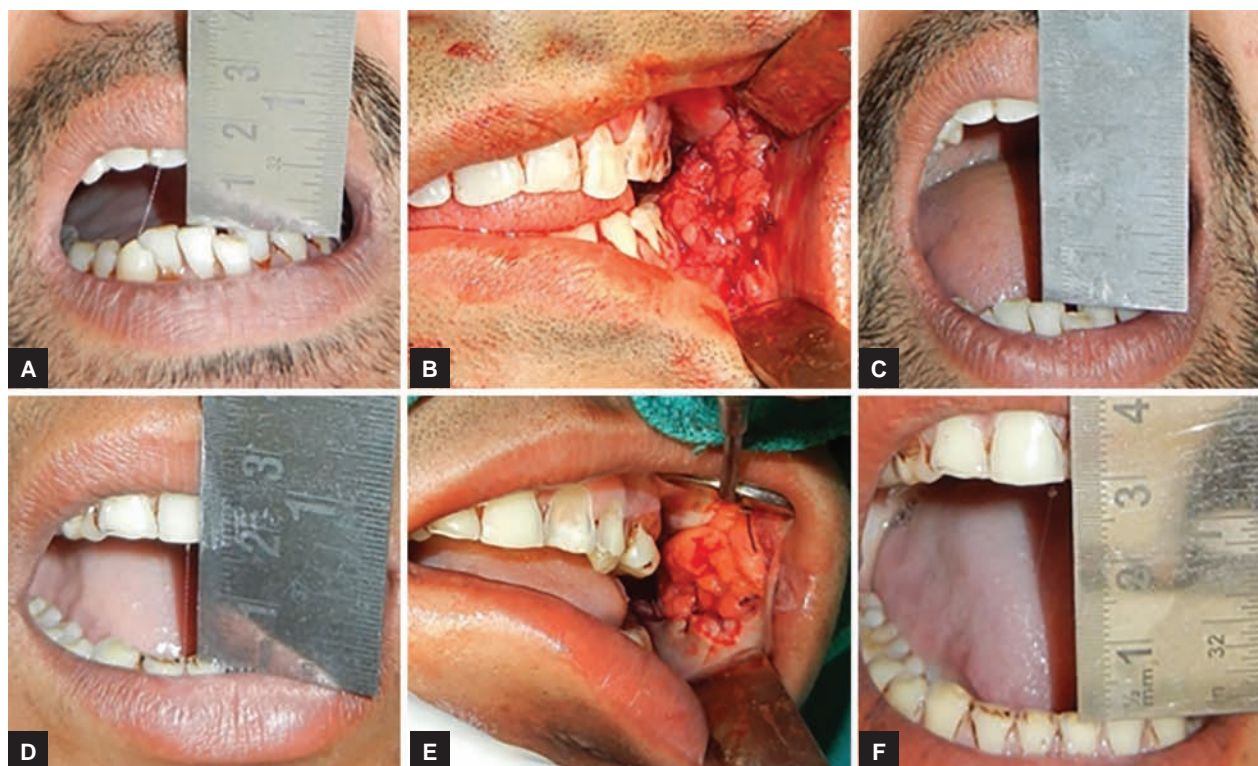
approached via posterosuperior margin of the created buccal defect, i.e., posterior to the zygomatic buttress. After blunt dissection through the submucosa, the BFP was teased out gently until significant amount was obtained to cover the defect without tension. It was found that technically BFP can be easily accessed and mobilized without undue stretching. Bilateral buccal defects of approximately  $3 \times 2$  to  $4 \times 2.5$  cm can be covered with BFP grafts without noticeable defects in the cheeks or mouth after hemostasis.<sup>18,19</sup> The BFP was then secured in place with sutures using Vicryl 3-0, as standard in all patients (Figs 3 to 5).

In group II patients, following excision of bands and forceful mouth opening intraoperatively, the raw wound was covered using collagen membrane. The material is available in thickness of 0.3 to 0.6 mm and in a range of dimensions. The size used for most of the cases in the present study was  $0.6 \text{ mm} \times 5 \text{ cm} \times 5 \text{ cm}$ . The material was reconstituted by immersion in normal saline for 5 minutes, and then cut with scissors to required shape, leaving a small overlap on the remaining mucous membrane. The graft was sutured with 3-0 Vicryl to attain close approximation to the underlying tissues.<sup>20-22</sup>

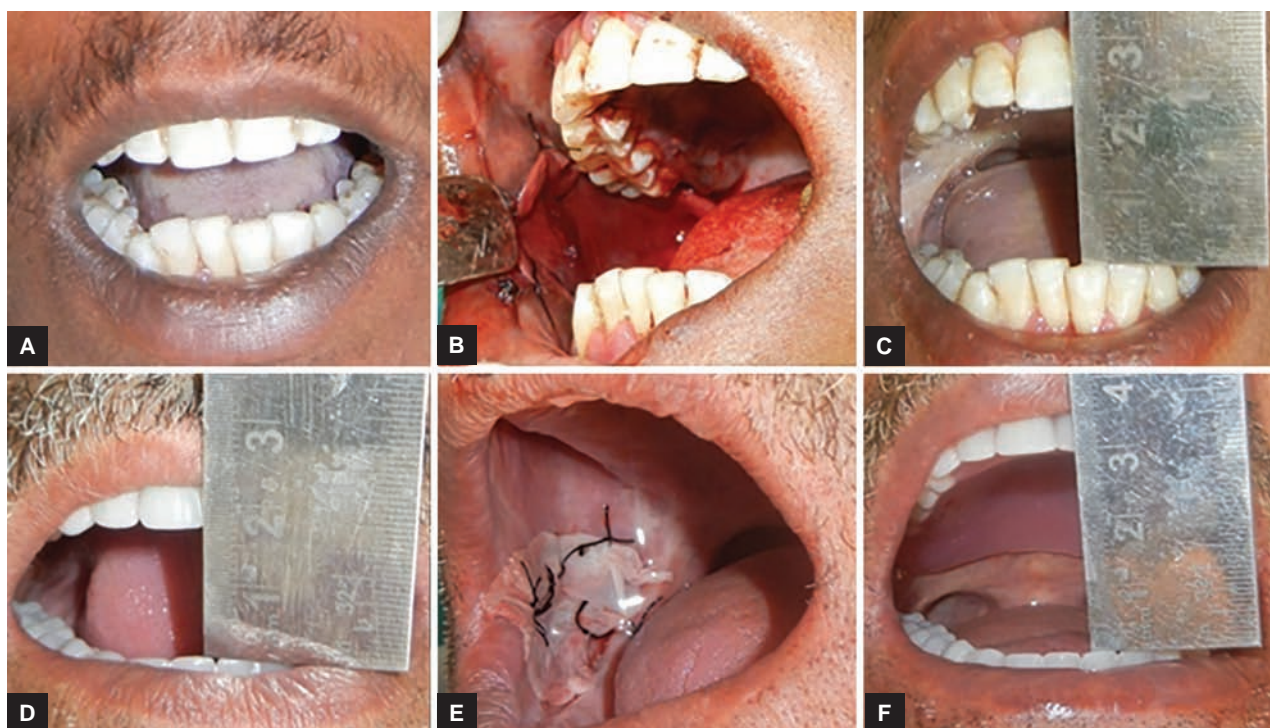
All patients received course of antibiotics, IV fluids for next 12 hours, anti-inflammatory drugs, and analgesics and cold sponging to cheeks for 48 hours and liquid diet for 5 days. Nasogastric feeding was given for 3 days and intensive physiotherapy was started within 48 hours



**Figs 3A to F:** (A) Preoperative mouth opening; (B) bilateral excision of bands; (C) intraoperative forceful opening; (D) BFP used as a graft for group I; (E) collagen membrane used as a graft for group II; and (F) postoperative opening at 6 months



**Figs 4A to F:** (A) Preoperative opening in patient 1; (B) intraoperative placement of BFP; (C) postoperative mouth opening achieved; (D) preoperative opening in patient 2; (E) intraoperative placement of BFP; and (F) postoperative mouth opening achieved



**Figs 5A to F:** (A) Preoperative opening in patient 3; (B) intra-op placement of collagen membrane; (C) postoperative mouth opening achieved; (D) preoperative opening in patient 4; (E) intraoperative placement of collagen membrane; and (F) postoperative mouth opening achieved

postoperatively using Heister's mouth gag. Patients were discharged with mouth opening measurement, with strict instructions regarding continuance of intense mouth opening exercises and discontinuance of habits. Patients

were recalled till epithelialization was completed and thereafter for regular follow-up after 1, 3, and 6 months. The results obtained were analyzed using Student's t test and chi-square test.

## OBSERVATIONS AND RESULTS

In the present study, 30 patients were taken up for evaluation of efficacy of BFP and collagen membrane in surgical management of OSMF.

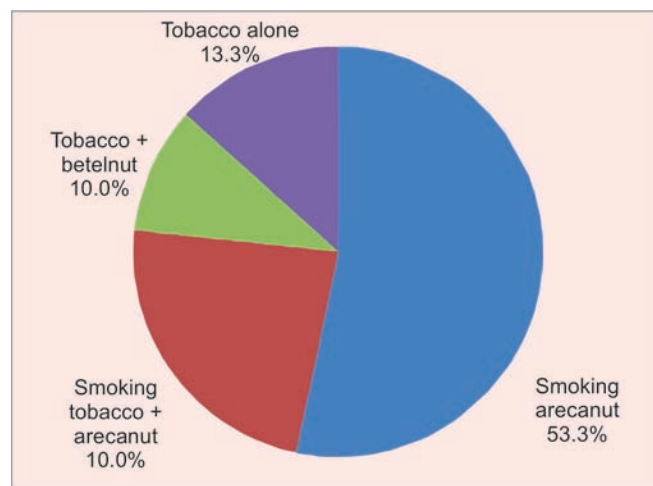
The collagen membrane (group II) proved to be more efficient and the result was statistically significant as it showed better mouth opening postoperatively at 6 months, improvement in flexibility of buccal mucosa, reduction in postoperative pain and burning sensation, and faster epithelialization rate compared with BFP (group I).

Thirty patients were included in the study, with age group 20 to 50 years. Sex predilection favored predominantly males.

Results of all the parameters are shown in Graphs 1 to 6.

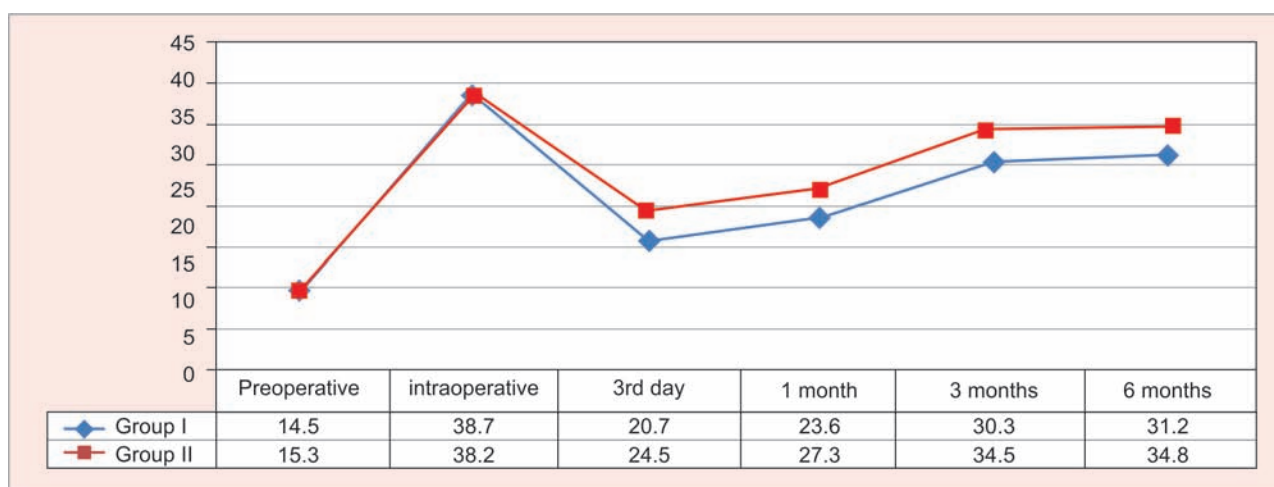
## DISCUSSION

Oral submucous fibrosis is a chronic, progressive pre-cancerous condition of oral mucosa, predominantly seen in the Indian subcontinent. A progressive inability to open the mouth fully is an important feature in OSMF

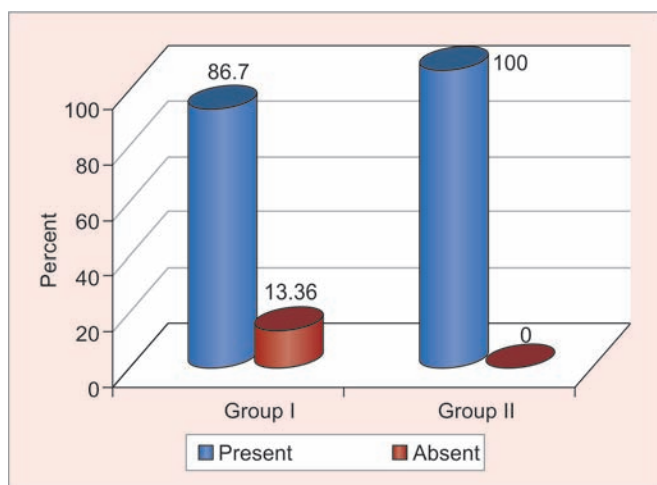


Graph 1: Habit distribution of the study group

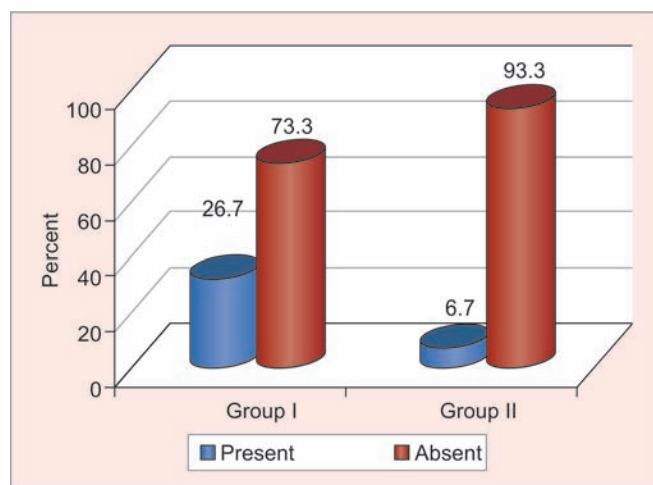
due to the formation of fibrous bands, especially in the buccal mucosa, posterior palate, and lips. The basic aim of any treatment modality is to relieve the symptoms that include burning sensation in the mouth, ulceration and stiffness of the oral mucosa, and progressive limitations



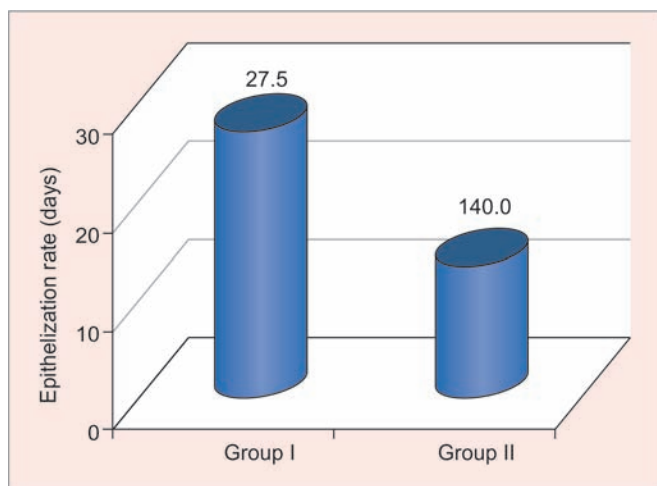
Graph 2: Mouth opening at various stages



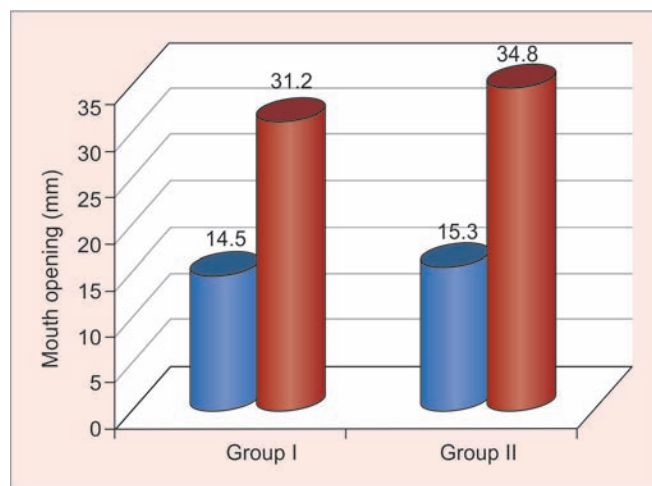
Graph 3: Improvement in flexibility of buccal mucosa



Graph 4: Postoperative pain and burning sensation



**Graph 5:** Epithelialization rate (days)



**Graph 6:** Comparative evaluation of increase in mouth opening in both the study groups

in mouth opening, thereby tampering the functions like deglutition and speech.<sup>15,23</sup>

Relapse is a common complication that occurs after surgical release of the oral trismus caused by OSMF. Initially surgeons aimed at surgical elimination of the fibrotic bands which showed further scar formation and reoccurrence of trismus; hence, to prevent scar, they started using various interpositional graft material.<sup>24</sup>

Use of island palatal flap has limitation, such as its involvement with fibrosis and second molar tooth extraction is required for flap to cover without tension.<sup>25</sup> Bilateral palatal flaps leave a large raw area on palatal bones. Sometimes the defect created may be large and local flaps may not be able to cover the entire defect. A nasolabial flap is too short to cover the defect and causes visible scarring on the face.<sup>26</sup> Tongue flaps have been used to cover the buccal defects but were found to be bulky and needed additional surgery for detachment. Bilateral tongue flaps can cause severe dysphagia and disarticulation and carry the risk of postoperative aspiration.<sup>27-29</sup> Pindborg et al found an incidence of 38% tongue involvement in OSMF, which precludes its use. Bilateral free radial artery forearm free flaps require microvascular expertise, the flaps are hairy, and 40% of patients require secondary debulking procedures. Extraction of third molar tooth is required to avoid flap inclination between teeth.<sup>24,30-33</sup>

Buccal fat pad by virtue of its anatomic position and the ease with which it can be accessed and mobilized without causing any noticeable defect in the cheek or mouth was felt to be a reliable interposition material. The procedure, considering the anatomic proximity of the donor and the recipient site, is not a prolonged one. The graft can be approached through the same buccal incision, which was used to release the fibrosis. Should it fail, the consequences are not serious, as other options are open.

The bulk of BFP in our series was found to be adequate in all cases and it maintained its position as interposition material postoperatively, similar to the findings of Lai, Yeh, and Rapidis and Ganizo.

In our study, the postoperative mouth opening in group I subjects (who received BFP graft) was of mean value of 31.2 mm. Improvement in the physiologic functions like suppleness and elasticity of the buccal mucosa on clinical examination did indeed have a good correlation with the original study conducted by Yeh.<sup>15</sup> The graft began to show signs of epithelialization from 3 to 4 weeks, with mean value of 27.5 days. This observation is similar to studies done by Martin-Granizo et al<sup>33</sup> and Ferrari et al.<sup>34</sup>

One patient in our series experienced a relapse, which unfortunately was due to the noncooperation of the patient with regard to postoperative mouth opening exercises. Recent experiments have shown that biological dressing creates the most physiological interface between the wound surface and the environment, and permits the body's reparative and immune system to function most efficiently. Collagen dressing used in the study is a kind of biological dressing composed of type I and type III bovine collagen, i.e., similar to human collagen. We used collagen membrane following excision of fibrotic bands in group II subjects to cover the raw areas during initial phase of healing. It was observed that collagen membrane had good adaptability to the surgical defect, i.e., it was supple and adapted to the wound no matter what the contour was.<sup>35,36</sup> Based on a study by Natraj et al<sup>37</sup> collagen membrane, though not statistically significant, gave better results compared with BFP with respect to mouth opening, whereas our study also showed collagen to be more efficient, and overall, the results are statistically significant.

None of the cases showed any adverse reactions to the collagen, proving its safety as a biological dressing. This

result is in accordance with that of Mitchell.<sup>38</sup> Granulation and epithelialization was good and wound contracture was far less comparatively. The appearance of grafted area was restored to normal texture in about 2 weeks. After 6 months follow-up, the postoperative mouth opening was of mean value of 34.8 mm. Because of the simple application and good tolerance of the membrane by oral tissues, collagen can be advocated as a temporary dressing material in orofacial region. It is an alternative to autologous grafts rather than being a replacement of other grafts used in orofacial region and can be viewed as a satisfactory additional armamentarium to oral surgeons.<sup>37,39</sup>

Whatever the graft being used, the treatment should be coupled with cessation of betel quid/gutkha chewing and daily mouth opening exercises, and proper nutrition in order to manage both early and advanced stages of OSMF.

## CONCLUSION

The advantages of collagen over BFP were observed as follows:

- The material is readily available and easily reconstituted for simple chair-side technique.
- The collagen membrane remained moist, supple, and intact when grafted.
- It was effective in promoting hemostasis.
- It acted as a temporary covering material on the sensitive nerve endings of raw wounds, which reduced the postoperative pain.
- It acted as a mechanical barrier preventing wound contamination.
- It appears to be sufficiently robust to withstand masticatory trauma.
- The collagen membrane did not evoke any antigenic reactions.
- It was useful in inducing granulation and epithelialization and in preventing the degree of scarring and tissue contracture.

No doubt, there are various variables affecting patient compliance, both positively and negatively, including patient motivation, the nature and chronicity of the disease, treatment variables, and the quality of the patient–doctor relationship. Therefore, early and intensive postoperative rehabilitation is the most important factor in maintaining the ID. For this reason, psychologic preparation of the patient before surgery plays a significant role in the success of surgery. In turn, greater compliance positively affects mouth opening management and therefore, patient satisfaction with the outcome of treatment.<sup>40</sup>

## REFERENCES

1. Rajendran R. Oral submucous fibrosis: etiology, pathogenesis, and future research. *Bull World Health Organ* 1994;72(6): 985-996.
2. Shah N, Sharma PP. Role of chewing and smoking habits in the etiology of oral submucous fibrosis (OSF): a case-control study. *J Oral Pathol Med* 1998 Nov;27(10):475-479.
3. Shah B, Lewis MAO, Bedi R. Oral submucous fibrosis in a 11-year-old Bangladeshi girl living in the United Kingdom. *Br Dent J* 2001 Aug;191(3):130-132.
4. Ariyawardana A, Athukorala ADS, Arulanandam A. Effect of betel chewing, tobacco smoking and alcohol consumption on oral submucous fibrosis: a case-control study in Sri Lanka. *J Oral Pathol Med* 2006 Apr;35(4):197-201.
5. Bathi RJ, Parveen S, Burde K. The role of gutka chewing in oral submucous fibrosis: a case-control study. *Quintessence Int* 2009 Jun;40(6):e19-e25.
6. Ramadass T, Manokaran G, Pushpala SM, Naryanan N, Kulkarni GN. Oral submucous fibrosis – new dimensions in surgery. *Indian J Otolaryngol Head Neck Surg* 2005 Apr;57(2):99-102.
7. Tilakaratne WM, Klinikowski MF, Saku T, Peters TJ, Warnakulasuriya S. Oral submucous fibrosis: review on aetiology and pathogenesis. *Oral Oncol* 2006 Jul;42(6):561-568.
8. Kumar A, Bagewadi A, Keluskar V, Singh M. Efficacy of lycopene in the management of oral submucous Fibrosis. *Oral Surg Oral Med Oral Pathol Oral Radiol Endod* 2007 Feb;103(2):207-213.
9. Surej KKK, Kurien NM, Sakir N. Buccal fat pad reconstruction for oral submucous fibrosis. *Natl J Maxillofac Surg* 2010 Jul-Dec;1(2):164-167.
10. Khanna JN, Andrade NN. Oral submucous fibrosis: a new concept in surgical management. Report of 100 cases. *Int J Oral Maxillofac Surg* 1995 Dec;24(6):433-439.
11. Schlegel AK, Möhler H, Busch F, Mehl A. Preclinical and clinical studies of a collagen membrane (Bio-Gide). *Biomaterials* 1997 Apr;18(7):535-538.
12. Güngörmü M, Kaya O. Evaluation of the effect of heterologous type I collagen on healing of bone defects. *J Oral Maxillofac Surg* 2002 May;60(5):541-545.
13. Sculean A, Berakdar M, Chiantella GC, Donos N, Arweiler NB, Brex M. Healing of intrabony defects following treatment with a bovine-derived xenograft and collagen membrane. A controlled clinical study. *J Clin Periodontol* 2003 Jan;30(1): 73-80.
14. Proussaefs P, Lozada J. The use of resorbable collagen membrane in conjunction with autogenous bone graft and inorganic bovine mineral for buccal/labial alveolar ridge augmentation: a pilot study. *J Prosthet Dent* 2003 Dec;90(6): 530-538.
15. Yeh CJ. Application of the buccal fat pad to the surgical treatment of oral submucous fibrosis. *Int J Oral Maxillofac Surg* 1996 Apr;25(2):130-133.
16. Jeevan Kumar KA, Brahmaji Rao J. Versatility of pedicled buccal fat pad in surgical management of oral submucous fibrosis – a study in 20 cases. *Indian J Dent Adv* 2009;1:5-11.
17. Rattan V. A simple technique for use of buccal pad of fat in temporomandibular joint reconstruction. *J Oral Maxillofac Surg* 2006 Sep;64(9):1447-1451.
18. Baumann A, Ewers R. Application of the buccal fat pad in oral reconstruction. *J Oral Maxillofac Surg* 2000 Apr;58(4): 389-392.
19. Singh J, Prasad K, Lalitha RM, Ranganath K. Buccal pad of fat and its applications in oral and maxillofacial surgery: a review of published literature 2004 to 2009. *Oral Surg Oral Med Oral Pathol Oral Radiol Endod* 2010 Dec;110(6):698-705.

20. Bunyaratavej P, Wang HL. Collagen membranes: a review. *J Periodontol* 2001 Feb;72(2):215-229.
21. Omura S, Mizuki N, Horimoto S, Kawabe R, Fujita K. A newly developed collagen/silicone bilayer membrane as a mucosal substitute: a preliminary report. *Br J Oral Maxillofac Surg* 1997 Apr;35(2):85-91.
22. Sader R, Seitz O, Kuttenger J. Resorbable collagen membrane in surgical repair of fistula following palatoplasty in nonsyndromic cleft palate. *Int J Oral Maxillofac Surg* 2010 May;39(5):497-499.
23. Lai DR, Chen HR, Lin LM, Huang YL, Tsai CC. Clinical evaluation of different treatment methods for oral submucous fibrosis. A 10-year experience with 150 cases. *J Oral Pathol Med* 1995 Oct;24(9):402-406.
24. Amin MA, Bailey BM, Swinson B, Witherow H. Use of the buccal fat pad in the reconstruction and prosthetic rehabilitation of oncological maxillary defects. *Br J Oral Maxillofac Surg* 2005 Apr;43(2):148-154.
25. Rapis AD, Alexandridis CA, Eleftheriadis E, Angelopoulos AP. The use of the buccal fat pad for reconstruction of oral defects: review of the literature and report of 15 cases. *J Oral Maxillofac Surg* 2000 Feb;58(2):158-163.
26. Maria A, Sharma Y, Kaur P. Use of nasolabial flap in the management of oral submucous fibrosis – a clinical study. *People's J Sci Res* 2011 Jan;4(1):28-30.
27. Mehrotra D, Pradhan R, Gupta S. Retrospective comparison of surgical treatment modalities in 100 patients with oral submucous fibrosis. *Oral Surg Oral Med Oral Pathol Oral Radiol Endod* 2009 Mar;107(3):e1-e10.
28. Krishna Prasad L, Chakravarthy PS, Sridhar M, Ramkumar S, Krishna S, Vivekanand SK. An evaluation of various surgical treatment modalities in the management of oral sub mucous fibrosis – a clinical study. *J Orofac Sci* 2009 Jan;1(2):17-20.
29. Gnanam A, Kannadasan K, Venkatachalapathy S, David J. Multimodal treatment options for oral submucous fibrosis. *SRM Univ J Dent Sci* 2010;1(1):26-29.
30. Shah A, Raj S, Rasaniya V, Patel S, Vakade M. Surgical management of oral submucous fibrosis with the “Opus-5” diode laser. *J Oral Laser Appl* 2005 Jan;5(1):37-43.
31. Mokal NJ, Raje RS, Ranade SV, Prasad JS, Thatte RL. Release of oral submucous fibrosis and reconstruction using superficial temporal fascia flap and split skin graft—a new technique. *Br J Plast Surg* 2005 Dec;58(8):1055-1060.
32. Lee JT, Cheng LF, Chen PR, Wang CH, Hsu H, Chien SH, Wei FC. Bipaddled radial forearm flap for the reconstruction of bilateral buccal defects in oral submucous fibrosis. *Int J Oral Maxillofac Surg* 2007 Jul;36(7):615-619.
33. Martin-Granizo R, Naval L, Castas A, Goizueta C, Rodriguez F, Monje F, Muñoz M, Diaz F. Use of buccal fat pad to repair intraoral defects: review of 30 cases. *Br J Oral Maxillofac Surg* 1997 Apr;35(2):81-84.
34. Ferrari S, Ferri A, Bianchi B, Copelli C, Magri AS, Sesenna E. A novel technique for cheek mucosa defect reconstruction using a pedicled buccal fat pad and buccinator myomucosal island flap. *Oral Oncol* 2009 Jan;45(1):59-62.
35. Lin HJ, Lin JC. Treatment of oral submucous fibrosis by collagenase: effects on oral opening and eating function. *Oral Dis* 2007 Jul;13(4):407-413.
36. Herford AS, Akin L, Cicciu M, Maiorana C, Boyne PJ. Use of a porcine collagen matrix as an alternative to autogenous tissue for grafting oral soft tissue defects. *J Oral Maxillofac Surg* 2010 Jul;68(7):1463-1470.
37. Nataraj S, Guruprasad Y, Shetty JN. A comparative clinical evaluation of buccal fat pad and collagen in surgical management of oral sub mucous fibrosis. *Arch Dent Sci* 2011 May;2(4):17-24.
38. Mitchell R. Treatment of fibrinolytic alveolitis by a collagen paste (formula k). A preliminary report. *Int J Oral Maxillofac Surg* 1986 Apr;15(2):127-133.
39. Rastogi S, Modi M, Sathian B. The efficacy of collagen membrane as a biodegradable wound dressing material for surgical defects of oral mucosa: a prospective study. *J Oral Maxillofac Surg* 2009 Aug;67(8):1600-1606.
40. Huang IY, Wu CF, Shen YS, Yang CF, Shieh TY, Hsu HJ, Chen CH, Chen CM. Importance of patient's cooperation in surgical treatment for oral submucous fibrosis. *J Oral Maxillofac Surg* 2008 Apr;66(4):699-703.